

# TIBIAL PLATEAU LEVELING OSTEOTOMY

## FOR TREATMENT OF A RUPTURED CRANIAL CRUCIATE LIGAMENT

The most common cause of rear limb lameness in the dog is rupture of the cranial (anterior) cruciate ligament. This derangement results in degenerative changes (osteoarthritis) in the stifle (knee) joint, including cartilage damage, osteophyte (bone spur) production, and meniscal injury. The Tibial Plateau Leveling Osteotomy (TPLO) has proven effective in returning these deranged stifles to full function.

### BIOMECHANICS

Although the knee joints of dogs and humans are similarly constructed, the forces applied to the surfaces of these joints during weightbearing are vastly different. This is due to the differences in anatomic configuration. Just as a car resting on a flat surface has no tendency to roll, in humans, the hip, knee, and ankle joints are parallel to each other and perpendicular to the weightbearing surface (foot). We can stand easily with little stress on any ligamentous structure. Dogs, however, stand on their toes with their ankles up in the air and their knees bent forward (Fig. 1). The upper portion of the canine tibia (the tibial plateau) is sloped. Weightbearing creates a force that pushes the femur down the sloping tibial plateau, thereby moving the tibia forward. This force is the cranial tibial thrust. It is opposed only by the cranial cruciate ligament (Fig. 2). Just as a car resting on a hill would tend to roll down the hill, the ligament acts as a cable attached to the car to resist that downhill roll (Fig. 3A). With every step a dog takes, stress is

applied to the ligament. Over time, dogs with a high tibial plateau slope (like a steep driveway) place enormous stress on the ligament. Therefore, when the cranial tibial thrust is too great, the cranial cruciate ligament ruptures (Fig. 4).

Ruptures come in several varieties. There are singular incidents which cause a sudden complete rupture with severe pain and a nonweightbearing lameness. Other ruptures occur in small increments or a little bit at a time. These are known as partial ruptures of the cranial cruciate ligament. They cause a small amount of pain and a mild lameness with poor performance. When partial ruptures proceed to complete ruptures, the transition is often gradual.

Two other important structures in the knee are the medial and lateral menisci (cartilage pads) (Fig. 1). They are also prone to injury when the stifle is unstable from a cruciate ligament tear.

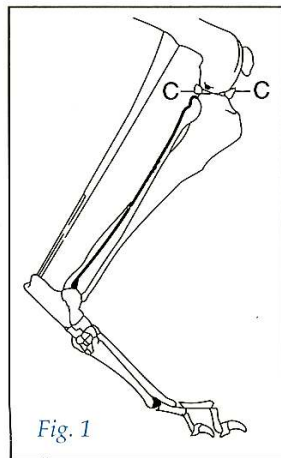


Fig. 1

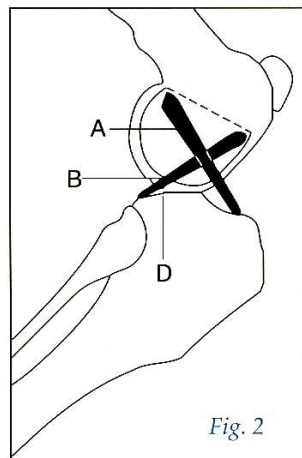


Fig. 2

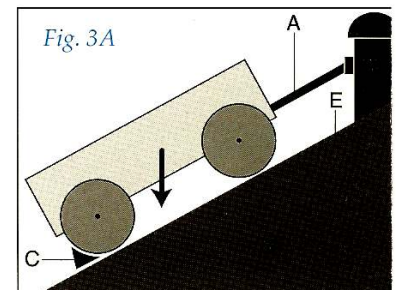


Fig. 3A

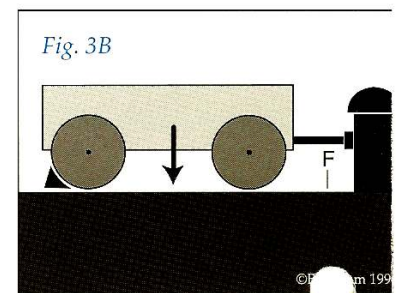


Fig. 3B

A=CRANIAL CRUCIATE LIGAMENT  
 B=CAUDAL CRUCIATE LIGAMENT  
 C=MENISCUS  
 D=TIBIAL PLATEAU

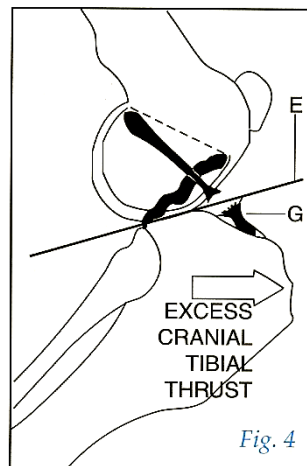
The TPLO procedure is most applicable to active individuals due to the inherent stability it provides under extreme repetitive stress. Traditional surgery in these individuals requires prolonged confinement to allow healing of the synthetic or natural cranial cruciate ligament replacement. These materials may fail because confining these active individuals for prolonged recovery periods can be all but impossible. Any activity may lead to stretching the artificial and collateral ligaments, incomplete flexion of the stifle, poor athletic performance and an incomplete return of thigh diameter.

## ■ CLINICAL SIGNS

Once the cranial cruciate ligament ruptures, the tibia can slide forward and the femur is free to ride down the slope of the tibial plateau, just as the car rolls down the hill once the cable is cut (Fig. 3A). The meniscus is often damaged as the femur rides over the top of it. When the ligament tears, pain, swelling in the knee, and marked lameness will occur. If not stabilized, the joint will become dramatically arthritic over time. Rest and antiinflammatory medications have little effect upon the pain and lameness the dog experiences.

## ■ DIAGNOSIS

The diagnosis is made upon eliciting forward motion of the tibia (cranial drawer sign). This is easy in acute, complete ruptures, but may be more subtle in chronic or partial tears. Mild sedation to allow muscle relaxation and radiographs (x-rays) to demonstrate arthritic changes and swelling may be necessary to obtain a diagnosis.

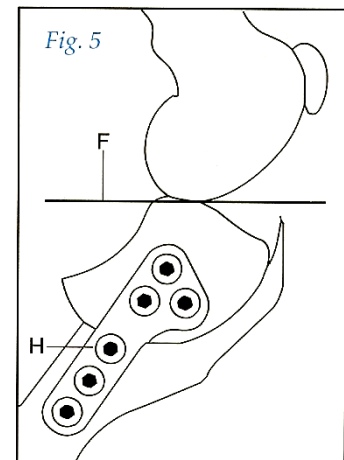


## ■ TPLO SURGERY

The Tibial Plateau Leveling Osteotomy is used to neutralize the effect of cranial tibial thrust (Fig. 5). The procedure "levels" the tibial plateau, thereby eliminating the need for the cranial cruciate ligament as a restraint against cranial tibial thrust (Fig. 3B). *In other words, rather than replacing the cable which broke in the first place, this procedure will level the surface and eliminate the need for the cable.* Meniscal injuries are also corrected during the surgery in order to prevent further arthritic changes in the joint.

## ■ POSTOPERATIVE CARE

Healing takes about two months for the bone and slightly longer for the soft tissues. Strict confinement is mandatory during the healing process. Because the plateau leveling allows the joint pain to rapidly subside, the major problem during recovery is excessive patient activity prior to the completion of bone healing. Most patients return to controlled activity 2 months, and full activity in 3-4 months. Patients can return to athletic competition (field trials, hunting, agility trials, Schutzhund) usually by 6 months postoperatively.



E=SLOPED TIBIAL PLATEAU  
 F=LEVELED TIBIAL PLATEAU  
 G=RUPTURED CRANIAL CRUCIATE LIGAMENT  
 H=BONE PLATE AND SCREWS

Veterinary Surgical Services  
215 Center Park Drive  
Knoxville, TN 37922  
**(865) 966-3920**

**OPERATIVE REPORT**

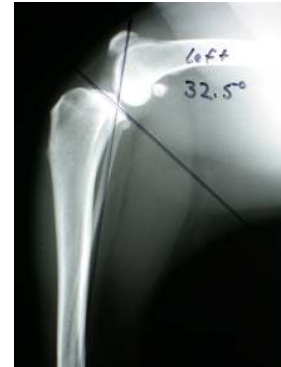**Case No :** 0000

**Ref Vet:** Sample Report DVM

**Patient:** Abby Sample

**Date:**

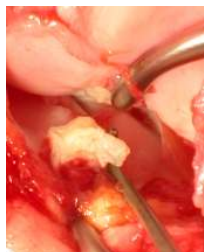**Pre Op Dx:** Palpation reveals bilateral ACL ruptures. Palpation demonstrates cranial draw and meniscal click bilaterally. Tibial trust as well as medial compartmental swelling is present bilaterally. Dog is most symptomatic in left rear.



**Pre-Op Notes:** Pre operative X-Rays were taken of the left rear leg. Slope measurements were calculated at 32.5 degrees. There was evidence of DJD. A meniscal clicking was present on palpation. Cefazolin was given IV at 800mg IV. 2ml Rimadyl SQ. Fentanyl patch was placed by referring Veterinarian.

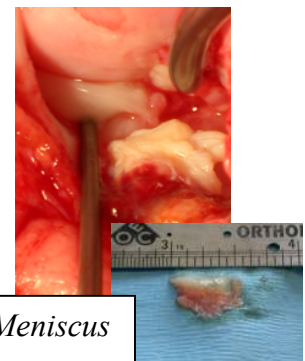
**Operation in Detail:** The left leg was cleaned and prepped for surgery. Next, the dog was placed in dorsal recumbency. The entire dog was draped so only the left rear leg was exposed in the field. A 12 cm incision was made on the medial surface of the right rear leg from approx 2 cm medially from the patella, extending distally to approximately the proximal third of the tibia. A linear incision was made through the distal medial quadriceps over the medial aspect of the trochlear ridge to the interval between the tibial plateau and the straight patella tendon. The incision was extended distally through the pes anserinus group medially to the tibial crest and through the fascia of the medial border of the cranial tibia muscle group.

A periosteal elevator is used to undermine the cranial muscle groups from the craniolateral aspect of the tibia while leaving the fascial attachments proximally and cranially. Medially, the fascia and tendinous extensions of the pes anserius (semitendinosus, gracilis, and caudal belly of the sartorius) were elevated from the tibia. The fascia along with the pes anserinus group were retracted caudally exposing the medial collateral ligament and popliteus muscle.



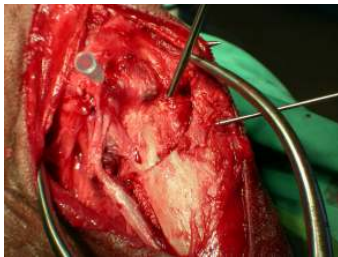
*Ruptured ACL*

Next the joint capsule was incised exposing the stifle joint and the ruptured ACL. There was a significant amount of debris including the large bucket tear of the posterior horn of the medial meniscus. A medial menisectomy was performed. The lat meniscus was wnl. The joint was flushed several times with warm saline. Marcaine was infused.



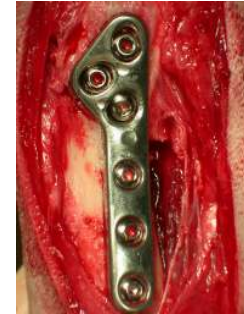*Medial Meniscus*

An incision was made on the medial margin of the popliteus from the insertion of the tibial head of the semimembranosus distally for approx 2cm. A small periosteal elevator was used to elevate the popliteus muscle from the tibia. A wet 4x4 was packed into the area to protect the muscle group and accompanying vessels and nerves. A 24 mm biradial saw blade was used to cut the proximal tibial perpendicular to the sagittal plane with the cranial curvature of the blade cranial to the tibial plateau and caudal to the tibial tubercle. The caudal curvature of the blade was aligned perpendicular to the caudal cortex of the tibia. Constant lavage was performed while the cut was made. With the osteotomy halfway down, the blade was withdrawn and the gauge was used to place the marks consistent with a 11.5 mm correction. The osteotomy was then resumed till completion. The two sponges were removed at this time.



A smooth IM pin was inserted just proximal the tibial plateau and directed caudally and slightly laterally. The pin was used to rotate the plateau until the marks match. A 1/6 inch partially threaded pin was placed proximal and lateral to the insertion of the straight tendon and inserted obliquely caudomedially and slightly distally into the tibial plateau fragment.

A 3.5 TPLO plate was contoured to the medial surface and applied with 3.5mm cortical screws starting with the three holes on the diaphyseal portion. The second hole of the TPLO plate was placed in compression and secured with a 4.0 cancellous screw. The 3<sup>rd</sup> hole was drilled in neutral. The 1<sup>st</sup> hole was drilled and the application was complete.

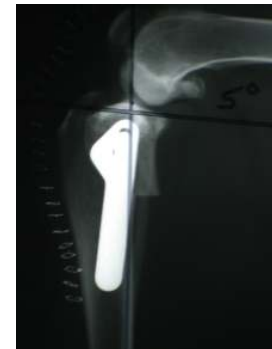

The joint capsule was closed with 0-PDS in a continuous pattern. Closure of the Pes anserinus group fascia to the prepared tibial crest fascia overlying the cranial tibial muscles was completed with 0 PDS in a continuous pattern along with mattress sutures placed in high tension areas. Next the subcutaneous tissue was closed with 0 PDS in a continuous pattern followed by 0 PDS in the Subcuticular with a continuous pattern. Skin staples were also applied.

**Post Operative Notes.** The slope was measured at 5 deg.

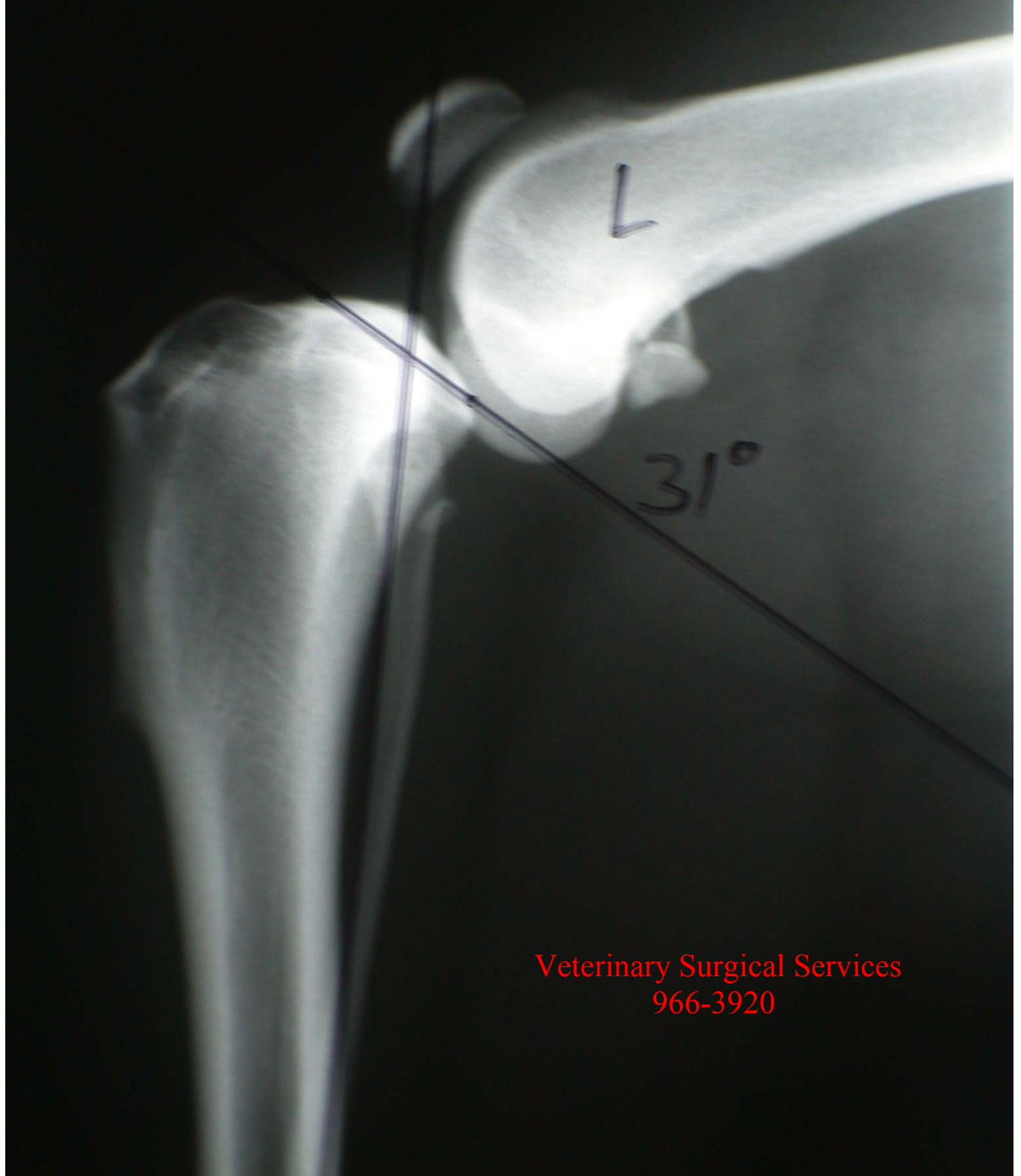#### **Post Operative Instructions:**

No Running , jumping or stairs. STRICT confinement. Follow instructions as provided. Keep away from slippery surfaces. Give antibiotics and pain meds as directed. Re-check and staple removal in 10-14 days. Re-check at 4 weeks post operative. Follow-up X-ray at 8 weeks. Refer to discharge instructions for post op care.



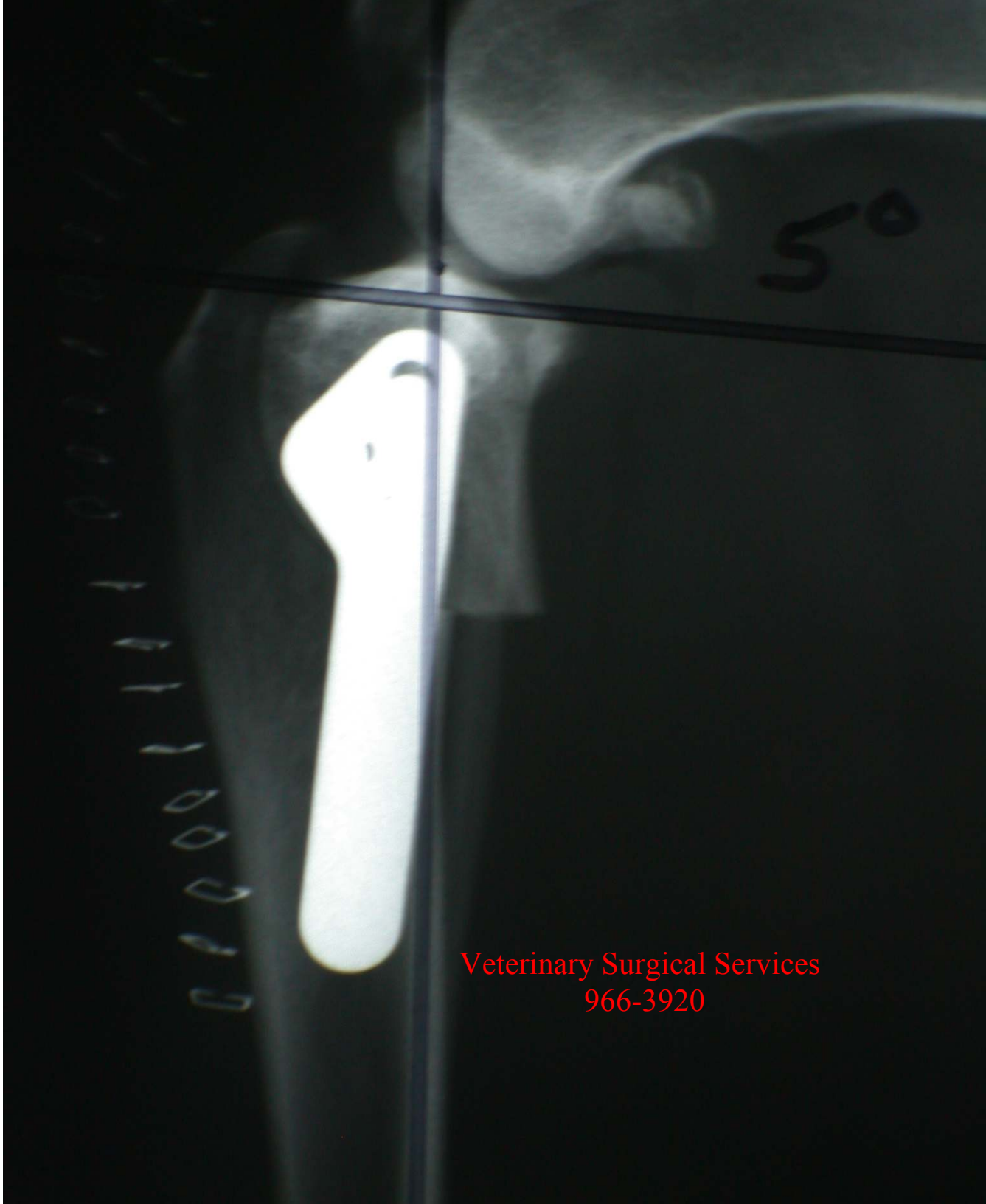Please call if you have any questions or problems.  
Mitch Rosenzweig, DVM

## Tibial Plateau Leveling Osteotomy Pre-Op Slope



Veterinary Surgical Services  
966-3920

# Tibial Plateau Leveling Osteotomy Post-Op Slope



Veterinary Surgical Services  
966-3920